



# Umbilical and epigastric hernia repair

Ulrike Muschaweck, MD, PhD

*Department of Hernia Surgery, Arabella-Klinik,  
Arabellastraße 5 81925, Munich, Germany*

“You see things; and you say, ‘Why?’ But I dream things that never were; and I say, ‘Why not?’”—George Bernard Shaw, “Back to Methuselah” (1921), Part 1, Act 1

About 10% of all primary hernias consist of umbilical and epigastric hernias [1]. Their repair therefore represents an important task in pediatric and adult surgery. Surprisingly, there is no consensus on how the repair should be done. Clinical trials and studies reporting experience with certain surgical procedures are also very scarce in the literature. There is one common thread, however: the Mayo operation with the overlapping technique dominated the field in the first half of the twentieth century [2].

As effective as this technique is for incisional hernia repair, it did not live up to expectations in umbilical and epigastric repair. More and more, surgeons had to acknowledge that the recurrence rate was much higher than expected, and a search for a new technique began. Although there are still many different methods being used, most surgeons agree on the need for a tension-free repair and on the use of bioprosthetic materials. I go even further and suggest a customized surgical technique tailored for each patient.

This article outlines the natural history and development of umbilical and epigastric hernias, comparing different surgical techniques and experiences found in literature, and presents my own studies and results.

## History and development

### *Umbilical hernia*

To fully understand the development of and consequently find the right treatment for umbilical and epigastric hernias, a look into embryology and anatomy is needed [3–5].

---

*E-mail address:* [info@hernien.de](mailto:info@hernien.de)

There are three types of umbilical hernias, which are classified by their actual time of development in life: (1) the congenital hernia, also called omphalocele; (2) the infantile; and (3) the adult umbilical hernia. The omphalocele can additionally be subdivided into two categories: fetal and embryonic.

The fetal omphalocele develops after week 8 in gestation when, normally, gut returns to the abdominal cavity. When that development does not occur naturally, a defect (<4 cm) in the abdominal wall is sustained. Bowel is herniated into only a sac of amnion that has the umbilical vessels located at the apex of the sac. Other anomalies are present in fewer than 10%. About 15% of congenital abdominal wall defects present with a fetal omphalocele.

In contrast to the fetal omphalocele, the embryonic omphalocele is due to failure of abdominal wall closure before week 8. It consists of a wide abdominal defect, in which the amnion does not protrude far beyond the abdomen. The umbilical cord joins the abdominal wall at the perimeter of the defect rather than at the apex. Bowel is herniated as well as liver. In these patients, multiple anomalies are present in 50%, such as congenital heart defects, trisomie 21, and renal abnormalities. The Beckwith-Wiedemann syndrome is one of the better-known syndromes.

In contrast to those severe abnormalities, the infantile umbilical hernia presents only a fascial defect at the umbilicus. It is always covered with skin and frequently present in newborns, especially in premature babies. The incidence is highest in blacks. In most children, the umbilical ring progressively diminishes in size and eventually closes. Defects less than 1 cm in diameter close spontaneously within 5 years in 95% of cases.

In all of the above malformations, surgical repair in general is indicated when

- the intestines become incarcerated
- the fascial defect is greater than 1 cm
- in girls over 2 years of age
- in all children over 4 years of age

In the nonmedical community it is always thought that the adult umbilical hernia results from persistence of infantile hernias. This is, however, not the case; the umbilical hernia of the adult is in almost 90% an acquired hernia [6] and represents an indirect herniation through an umbilical canal.

That canal has four borders: the umbilical fascia posteriorly, the linea alba anteriorly and the medial edges of the two rectus sheaths on each side. Herniation is due to a gradual yielding of the cicatricial tissue that closes the umbilical ring. This happens due to increasing intra-abdominal pressure.

Predisposing factors include extreme obesity, a history of multiple pregnancies with prolonged labor, ascites, and large abdominal tumors. Therefore, whenever an umbilical hernia is diagnosed, a coloscopy or computed tomography (CT) should be performed to rule out intestinal processes.

Umbilical hernias are in general more common in women than men and are associated with high morbidity and mortality. There is a high tendency of incarceration and strangulation and emergency repair is often necessary. The neck of the hernia is usually quite narrow compared with the size of the herniated mass, and strangulation is therefore common. Immediate repair after diagnosis is advised and should be done expeditiously.

### *Epigastric hernia*

The origin and development of the epigastric hernia is still an enigma. Although originally considered a congenital defect [7], it is now assumed that it is an acquired lesion [8].

Epigastric hernias protrude midline through the linea alba; therefore they are also called hernias of the linea alba. They occur most commonly above the level of the umbilicus, probably due to excessive strain of the abdominal wall aponeurosis.

It was long believed that epigastric hernias are congenital defects in the linea alba [9]; however, there are different studies published offering new possibilities of development. They all go back to an interesting study by Askar, who stresses that epigastric hernias only occur when there is a single midline pattern of decussation [10,11]. Then, there is also the belief of the vascular lacunae hypothesis outlined by Lang and colleagues [12]. To fully understand the true etiology, several institutes have tried to take biopsies of the linea alba and examine them thoroughly. Two studies from Germany and one from France were particularly interesting:

The team of Korenkov and Troidl in Germany undertook a biomechanical and histological investigation using 93 cadavers trying to check Askar's theory about the different levels of decussation in the linea alba [13]. They could not confirm his classification, however. Instead, they proposed a new classification dividing the linea alba into three types according to the thickness of the found fibers: the weak, the intermediate, and the compact type, with only the weak type predisposing for an epigastric hernia.

Another study from Germany, by the team of Axer and Prescher, also could not confirm Askar's fiber theory of separate lines of decussation and proposed a new model of fiber architecture consisting of a three-dimensional, highly structured meshwork of collagen fibers [14]. In this study, special concern was also given to the fibers of the rectus sheath, which have a rather complicated structure with many different places of origin. Given the complex structure and high importance of the rectus sheath in the functional anatomy of the abdominal wall, it is of concern that there are not many published studies about it in literature. The most important and thorough one goes back to 1967, written by Lange in Germany [15].

Leaving Germany and going to France, there is an interesting biomechanical study from the working group of Rath et al, using samples of the linea alba from 40 fresh cadavers and testing resistance, deformation, and

elasticity compared with prosthetic materials [16]. The dimension and width of the normal linea alba changes with patient age, sex, and also with location at, above, and below the level of the umbilicus.

This short outline shows that, in spite of many impressive efforts, the origin and development of hernias in the midline abdominal region still leaves room for discussion and offers an open invitation to researchers. More and extensive basic research would not be in vain, since the development of hernias in that region is not a rare incidence.

Approximately 3% to 5% of the population have epigastric hernias [1,17]. They are more common in men than in women, and the most affected age group ranges from 20 to 50 years. About 20% of epigastric hernias occur multiple, and about 80% are located just off the midline. Defects in the fascia may vary in diameter from only millimeters to several centimeters. The smaller hernias most frequently contain only preperitoneal fat and are especially prone to incarceration and strangulation. Larger hernias seldom strangulate and may contain also bowel and omentum. An epigastric hernia containing a peritoneal sac is also called a true hernia.

Most epigastric hernias should be repaired at time of diagnosis, since the small ones are likely to become incarcerated and larger ones are often symptomatic and unsightly.

## Choices of treatment

### *Infantile umbilical hernias*

Omphalocele with small abdominal defects can be treated easily by excising the omphalocele sac and reapproximating the linea alba and the skin. Most large omphalocele, however, cannot be closed without staging the procedure:

To invert the amniotic sac and its contents into the abdomen, a tube has to be sutured at the perimeter of the omphalocelic membrane. To successfully stretch the abdominal muscles, the tube is then progressively compressed. It can require a number of days to sufficiently relax the abdominals to allow rectus muscles to come together. The tube can then be removed; the amnion is left inverted into the abdominal cavity, and the defect in the linea alba is closed.

Nonoperative management is advised only for infants with severe associated anomalies. In those cases, the amnion is covered with bactericidal silver sulfadiazine, thus forming an eschar. Underneath, the membrane becomes vascularized and contraction of the wound with skin growth covers the defect.

The survival rate for infants with small omphalocele is excellent. Deaths associated with embryonic omphalocele are rare and result mostly from wound dehiscence with following infection or from grave, associated anomalies.

### *Adult umbilical hernia*

In the case of the umbilical hernia of the adult, surgical repair should be performed as early as possible. The presence of cirrhosis and ascites should not discourage repair, as strangulation, incarceration, and rupture are particularly dangerous in patients with these disorders. Significant ascites, however, should first be thoroughly treated, as morbidity and recurrence rate are much higher after hernia repair in patients with that condition [18].

### *Epigastric hernia*

Differential diagnosis of an epigastric hernia includes several different diseases such as peptic ulcer, gallbladder disease, pancreatitis, hiatal hernia, and upper small-bowel obstruction. Therefore, before setting the patient up for surgery, a precise medical work-up is necessary. It may be impossible to visibly distinguish the hernial mass from a subcutaneous lipoma, fibroma or neurofibroma, however. Ultrasound should be routinely performed and CT may additionally be needed to verify the diagnosis, especially in obese patients.

After the diagnosis of an epigastric hernia is confirmed, there is no reason to wait for surgical repair, as chances for incarcerations are high and surgery still represents the only permanent cure.

## **Methods of surgical repair: then and now**

### *The Mayo technique*

The most renowned surgical technique goes back to 1895, when William Mayo developed a technique for hernia repair that from then on was known as the Mayo operation and is still performed. He was the first surgeon to use a vertical overlap technique to repair an umbilical hernia, meaning overlapping the adjacent aponeurotic structures and thus securing a wide region of adhesion. His results were published in 1901 and 1903, when he had performed 25 repairs with good results and no sign of recurrence [2,19].

The conventional Mayo technique is still one of the most often chosen surgical techniques, performed routinely in hospitals all over the world, not only for repair of the umbilical or epigastric hernia, but also as standard technique for incisional hernia repair. Because it is very important to fully understand the Mayo technique to further develop it, a short description by Schumpelick and Kingsnorth [20] follows.

The operation starts with excision of abundant skin over the hernia and clearing the surface of the abdominal wall in all directions from the edge of the disrupted fascia.

As the next step, the hernial sac is prepared by dividing fibrous coverings.

Carefully, the sac is opened and its contents exposed and examined. Adhesions or scar tissue are carefully prepared and freed from intestinal viscera, if present.

So far the operation was a standard exploration, but the next steps define the typical Mayo technique:

First, the peritoneum is closed with a running, absorbable suture and the margins of the fascia are approximated to prepare for the overlapping.

The peritoneum is then separated from the lower surface of the overlay fascia.

Now the doubling of the fascia begins with nonabsorbable mattress sutures, beginning 3 cm from the margin of the overlay fascia, with the loop grasping the margin of the underlay fascia. Next, the free margin of the overlay fascia is fixed to the surface of the abdominal wall with nonabsorbable sutures.

As a last step, relaxing incisions in aponeurosis or in rectus sheaths 5 cm lateral to the suture are made to reduce excessive wound tension.

This technique clearly was almost revolutionary in the first half of the twentieth century and inspired surgeons all over the world until now. Considering its results, however, it has not lived up to its promise. Unfortunately, there are only very few randomized clinical trials published. There is a high rate of recurrence reported after the Mayo repair, however, with numbers ranging from 20% to 28% [21].

Due to the lack of a gold standard, the Mayo technique is still used, but is not favored by all surgeons anymore. David Bennett writes in the fifth edition of Nyhus and Condon's *Hernia* that the classic Mayo "vest-over-pants" technique had one major fault in that the bursting strength of the wound was directly impaired to a degree proportional to the overlapping and tension [22,23].

In Bennett's opinion, a fascial defect should be repaired by primary suture with nonabsorbable sutures and edge-to-edge closure. Another point he stresses is to save the original umbilicus if possible. The creation of a new umbilicus increases the risk of recurrence and should therefore be avoided. Bennett also advises that a prosthetic mesh should be inserted with large hernias when it is not possible to oppose the fascias without undue tension.

All techniques have in common that there are rare and minor complications like seroma, hematoma, and local infection. Interestingly enough, the true incidence of recurrence in these hernias is unknown; however, it appears that the numbers of incisional hernias are increasing.

Garcia-Urena et al write about a 15% rate of recurrence [24], and Pescovitz even gives a figure of 20% recurrence in patients with cirrhosis [25].

Given that high number of known recurrences and an even higher estimated unknown number, it was clear that the commonly used surgical techniques were insufficient and needed an update.

### *More recent techniques*

In recent years surgeons have tried to come up with an appropriate technique to sufficiently close the abdominal wall and creating an ideal tension-free repair.

In 1995, Celdran et al in Spain reported on their results using mesh prosthesis in 21 patients with umbilical hernia, 9 of whom presented with a recurrent hernia. Surgery itself presented no problem; the mesh was inserted without having to enlarge the defect, and after a mean follow-up of 13 months there was no recurrence [21].

Another promising technique is the Rives-Stoppa procedure developed for the repair of incisional hernias. Briefly, prosthetic material is used to close the defect in a so-called sublay technique. The prosthesis is placed between the rectus abdominis muscle and the posterior sheath. Bauer and colleagues in New York published a study with 57 patients [26], and Petersen and coworkers in Germany published a study of 50 patients [8] using the technique. Bauer had a mean follow-up of 34.9 months (11.7–81.9) with no recurrence (one prosthesis had to be removed). Petersen had an average follow-up of 19 months (5–44) and a recurrence rate of 10.4%. The disadvantage of this sublay technique is the need for an extensive preparation of the preperitoneal plane, and consequently a long time for the mesh implantation and overall surgery (165 minutes mean in the Petersen study).

Arroyo and coworkers in Spain performed one of the very few randomized clinical trials with 200 patients [27]. Their results showed a clear distinction between the success of using mesh repair and primary suture. The latter resulted in a recurrence rate of 11%, while after using a tension-free mesh repair it amounted to only 1%.

To give a complete picture of all techniques, the laparoscopic repair needs to be mentioned. There is a study from Wright and colleagues in Minneapolis with a comparative analysis of 105 umbilical hernias repaired in 112 patients [28] 30 laparoscopic mesh repairs, 20 open mesh repairs, and 55 open nonmesh repairs. Their study showed a trend of fewer postoperative complications and recurrences. This study, however, contradicts many other published studies and also my own experiences regarding the higher risk of laparoscopy versus open surgery and its high invasiveness.

### **Techniques at our hospital**

Our hospital specializes in hernia surgery, with an average of 1100 surgical repairs per year. I am the only chief surgeon, performing every single procedure myself. This constellation makes our hospital truly unique, because the standard of high-quality surgical skill is always achieved and maintained. Furthermore, results and follow-ups are a true reflection of the technique used and not of various surgical skills.

#### *Umbilical hernias*

##### *The technique*

Although most of our patients presented with groin hernias, the percentage of umbilical and epigastric hernias was quite high. From

January 1995 until February 2003 we operated on 210 patients with umbilical hernias. Eighty percent of the patients presented with primary hernias, 10% with a first recurrence, and 10% with a second recurrence.

Mean age of the patients was 54.6 years (18–79), with a female-to-male ratio of 3:4.

All patients had a follow-up from 6 to 60 months. The body mass index (BMI) was a mean of 23.4 kg/m<sup>2</sup> in female and 27.9 kg/m<sup>2</sup> in male. Associated diseases were known in 61% of all patients and included cardiac or respiratory problems, varicose veins, metabolic syndromes, or allergies.

The size of the defect varied from 0.5 cm to 4 cm intraoperatively.

All surgery was performed with local anesthesia. Here is a short description of our surgical technique: after infiltrating the umbilical region with Naropin, the umbilicus is excised caudally (Fig. 1). A partly sharp, partly blunt dissection of the sac follows (Figs. 2, 3). The defect is dissected circular from the sac and a closed reposition of the intact sac in toto is performed (Fig. 4).

Depending on the size of the orifice, an exact-fitting and tailored mesh plug is inserted and circularly fixated with a running suture, leaving part of the fascia edge untouched (Fig. 5). A tension-free adaptation of this free edge follows with a second running suture (Fig. 6). Afterwards the umbilicus

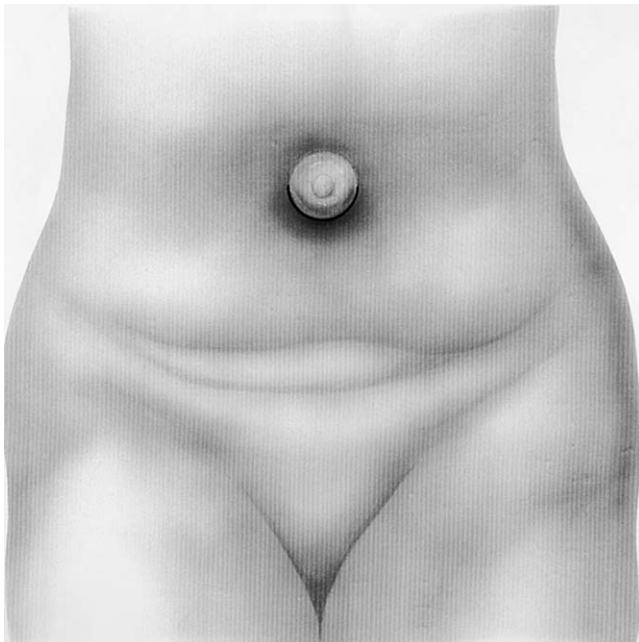


Fig. 1. Excision of umbilicus.



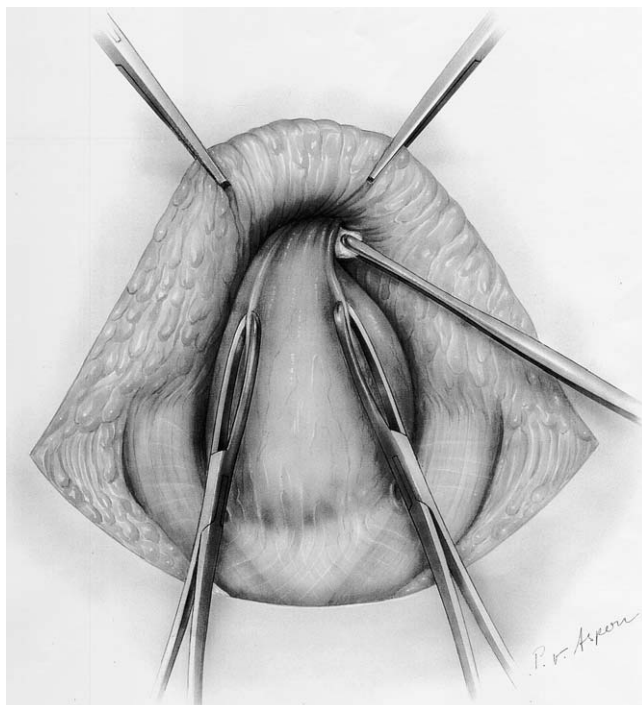


Fig. 2. Dissection of the sac (1).

is fixated at the anterior sheath of the rectal fascia. Wound adaptation with a running suture and subdermal single suture follows, and marks the end of the operation.

#### *Results after repair of a primary hernia*

In all but two cases a mesh plug was inserted. Complications were very rare and minor: three patients developed a seroma, only one patient on dialysis developed a minor necrosis around the umbilicus.

It is very important to stress that up to this day there has been no recurrence.

#### *Results of hernia repair after recurrence*

The body mass index of patients was significantly higher in this group, with a mean of 25.8 kg/m<sup>2</sup> in females and 29.8 kg/m<sup>2</sup> for males. Also the rate of associated diseases was higher and amounted to 71%. The defects ranged from 0.5 cm to 8 cm in size.

In all but one patient a mesh plug was inserted. Complications were minor and presented with seroma in three cases. In only one patient an

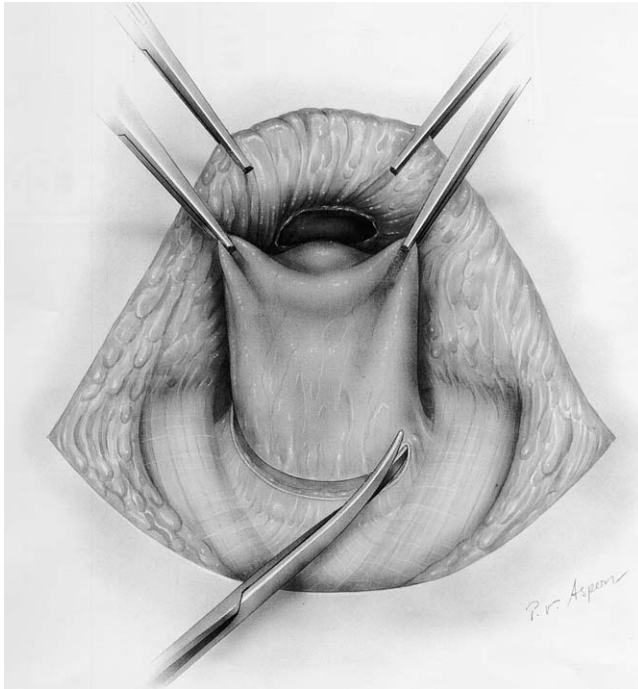


Fig. 3. Dissection of the sac (2).

incisional hernia developed after 9 months. All other patients showed no signs of recurrence.

### *Epigastric hernias*

#### *Other techniques*

As for epigastric hernias, the same debate over a perfect surgical solution has been going on for centuries. For smaller hernias, it is recommended to close the defect directly with a running suture. For larger hernias, the vest-over-pants Mayo technique is preferred. As with the Mayo repair of the umbilical hernia, however, the defect is artificially increased and there is undue tension to the newly formed plane.

In search of a better technique, in 1945 Berman published a description of a vertical Mayo-type repair, in which a vertical defect is created with a short anterior and long posterior flap on one side and the reverse on the other [29]. He then closed the defect in three layers and approximated the rectus muscles in the midline as a middle layer.

Askar, whose contributions to the repair of umbilical end epigastric hernias are vital once more, recommended fascial darning [10,11], meaning using strips of autologous fascia lata to close the defect. Today's use of inert polypropylene mesh has rendered that technique obsolete, however.

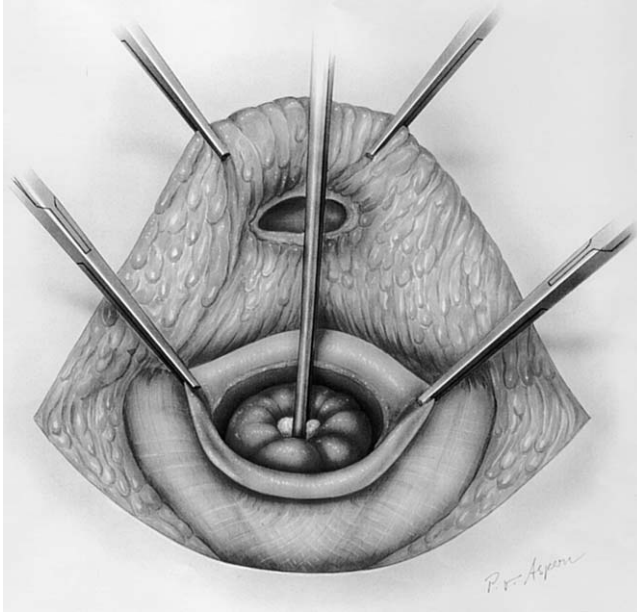


Fig. 4. Closed reposition of the sac.

The recurrence rate of epigastric hernia repair is 10% to 20%, a higher incidence than with the routine inguinal or femoral hernia repair. This high recurrence rate may be partly due to failure to recognize and repair multiple small defects.

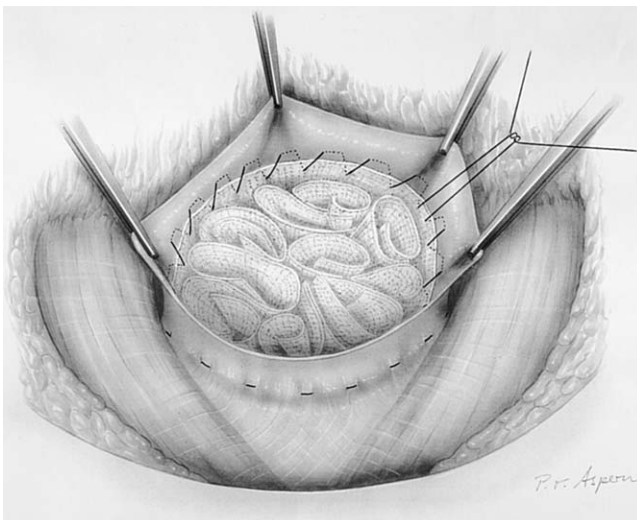


Fig. 5. Insertion of the mesh plug.

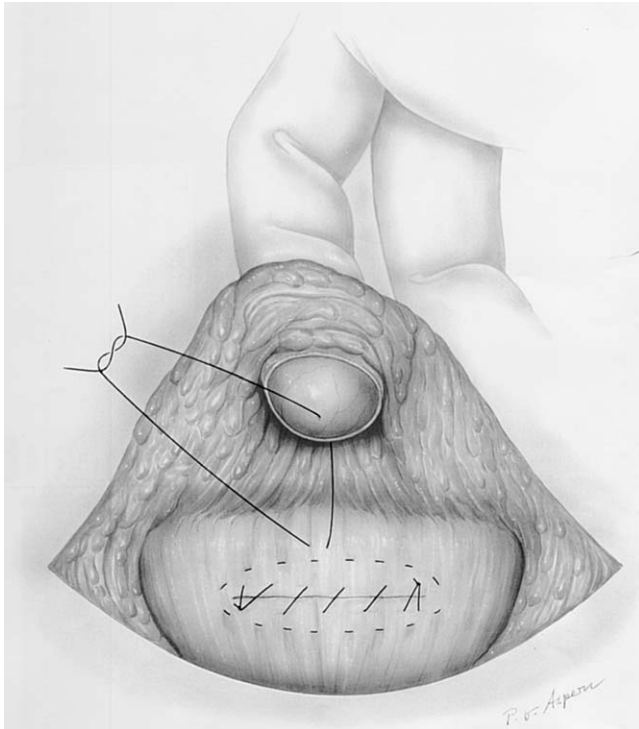


Fig. 6. Tension-free adaptation of the free edge.

### *Our technique*

From January 1995 until February 2003, my associates and I operated on 57 patients with epigastric hernias. 54 of the patients presented with primary hernias, 3 with a first recurrence.

Mean age of the patients was 50.1 years (25–76), with a female to male ratio of 4:7.

All patients had a follow-up from 4 to 60 months. The body mass index (BMI) was a mean of 27.5 kg/m<sup>2</sup>. Associated diseases were known in 69% of all patients and included cardiac or respiratory problems, varicose veins, metabolic syndromes, or allergies.

The size of the defect varied from 0.5 cm to 5 cm intraoperatively.

As with umbilical hernias, all surgery was performed under local anesthesia. Surgical technique was the same as explained above with the exception of a median cut instead of circumcising the umbilicus.

In all but four cases a mesh plug was inserted. Complications were very rare and minor: one patient developed a seroma.

All our patients were called in for a routine check-up after 6 months, 1 year, and 5 years postoperatively and none of them presented with a recurrent hernia.

### *Results of hernia repair after recurrence*

The body mass index of those patients was not significantly higher in this group, with a mean of 22.3 kg/m<sup>2</sup>. Also the rate of associated diseases was the same. The defects ranged from 0.5 cm to 2.5 cm in size.

In all patients a mesh plug was inserted. Complications were minor and presented with seroma in one case. No patients have shown signs of recurrence so far.

### **Summary**

The repair of umbilical and epigastric hernias still represents a challenge to surgeons. Although a common and relatively simple procedure, there is no exact protocol today on how the repair should be done. The Mayo technique and its alterations could not stand the test of time: a recurrence rate of 20% and higher is not acceptable for any surgical procedure.

Although there is no consensus opinion, one thing is clear: the importance of an anatomic repair without tension and without an artificial enlargement of the defect.

In 1987 Lichtenstein reported on 6321 cases of herniorrhaphy with a tension free repair [30], and in 1994 Stuart reemphasized that special importance in his editorial in the *Lancet* [31].

A newer study from Brancato and coworkers in Italy also states the advantage of a tension-free prosthetic repair in 16 patients with epigastric hernia [32].

We have gone even further and recommend a tailored-to-the-patient repair using a customized polypropylene mesh and a one-layer running suture. The advantages should be obvious: no artificial creation of an even bigger than original defect, a completely tension-free repair, and little to no recurrence of the hernia.

Our results clearly prove that assumption. Moreover, the procedure is extremely safe and complications are very rare and minor.

We conclude that using a mesh plug in a customized tension-free repair of umbilical and epigastric hernia shows many advantages over the commonly used methods.

And we finally conclude with the words of Albert Einstein: “The only source of knowledge is experience.”

### **References**

- [1] Klinge U, Prescher A, Klosterhalfen B, et al. Entstehung und Pathophysiologie der Bauchwanddefekte. *Chirurg* 1997;68:293–303.
- [2] Mayo WJ. An operation for the radical cure of umbilical hernia. *Ann Surg* 1901;34:276–80.
- [3] Blumberg NA. Infantile umbilical hernia. *Surg Gynaec Obst* 1980;150:187.
- [4] Langman J. Verdauungskanal und Anhangsorgane. In: *Medizinische Embryologie*. 5th edition. Stuttgart (Germany): Thieme; 1977. p. 261–300.

- [5] deLorimier AA, Harrison MR, Adzick NS. Pediatric surgery. In: Way LW, editor. Current surgical diagnosis and treatment. 10th edition. East Norwalk (CT): Appleton and Lange; 1994. p. 1190–237.
- [6] Jackson OJ, Moglen LH. Umbilical hernia: a retrospective study. *Calif Med* 1970;113:8.
- [7] Moschowitz AV. The pathogenesis and treatment of herniae of the linea alba. *Surg Gynecol Obstetric* 1914;18:504.
- [8] Petersen S, Henke G, Freitag M, et al. Experiences with reconstruction of large abdominal wall cicatricial hernias using Stoppa-Rives pre-peritoneal meshplasty. *Zentralblatt Chir* 2000;125(2):152–6.
- [9] Larson GM, Vandertoll MD. Approaches to repair of ventral hernia and full-thickness losses of the abdominal wall. *Surg Clin North Am* 1984;64(2):335–49.
- [10] Askar OM. A new concept of the aetiology and surgical repair of paraumbilical and epigastric hernias. *Ann R Coll Surg Engl* 1978;60:40–2.
- [11] Askar OM. Aponeurotic hernias. Recent observations upon paraumbilical and epigastric hernias. *Surg Clin North Am* 1984;64(2):315–33.
- [12] Lang B, Lau H, Lee F. Epigastric hernia and its etiology. *Hernia* 2002;6(3):148–50.
- [13] Korenkov M, Beckers A, Koebke J, et al. Biomechanical and morphological types of the linea alba and its possible role in the pathogenesis of midline incisional hernia. *Eur J Surg* 2001;167:909–14.
- [14] Axer H, von Keyserlingk D, Prescher A. Collagen fibers in linea alba and rectus sheaths. *J Surg Res* 2001;96:127–34.
- [15] Lange W. Über die Inscriptiones tendineae im Musculus rectus abdominis des Menschen. *Anat Anz* 1967;121:372–80.
- [16] Rath AM, Attali P, Dumas JL, et al. The abdominal linea alba: an anatomico-radiologic and biomechanical study. *Surg Radiol Anat* 1996;18:281–8.
- [17] Deveney KE. Hernias and other lesions of the abdominal wall. In: Way LW, editor. Current surgical diagnosis and treatment. 10th edition. East Norwalk (CT): Appleton and Lange; 1994. p. 712–24.
- [18] Kirkpatrick S, Schubert T. Umbilical hernia rupture in cirrhotics with ascites. *Dig Dis Sci* 1988;33:762.
- [19] Mayo WJ. Further experience with the vertical overlapping operation for the radical cure of umbilical hernia. *J Am Med Ass* 1903;41:225–8.
- [20] Decurtins M. Significance of fascia doubling in the management of incisional hernia. In: Schumpelick V, Kingsnorth AN, editors. *Incisional Hernia*. Berlin, Heidelberg: Springer; 1999. p. 287–93.
- [21] Celdran A, Bazire P, Garcia-Urena MA, et al. H-hernioplasty: a tension free repair for umbilical hernia. *Br J Surg* 1995;82:371–2.
- [22] Bennett D. Incidence and management of primary abdominal wall hernias: umbilical, epigastric and spigelian. In: Fitzgibbons RJ Jr, Greenburg AG, editors. *Nyhus and Condon's hernia*. 5th edition. Philadelphia: JB Lippincott co.; 2002. p. 389–98.
- [23] Farris JM. Umbilical hernia. In: Nyhus LM, Harkins HN, editors. *Hernia*. Philadelphia: JB Lippincott Co.; 1964. p. 315.
- [24] Garcia-Urena MA, Rico P, Seoane J, et al. Hernia umbilical del adulto. *Cirugia Española* 1994;56:302–6.
- [25] Pescovitz MD. Umbilical hernia repair in patients with cirrhosis. No evidence for increased incidence of variceal bleeding. *Ann Surg* 1984;199:325–7.
- [26] Bauer JJ, Harris MT, Gorfine SR, et al. Rives-Stoppa procedure for repair of large incisional hernias experience with 57 patients. *Hernia* 2002;6(3):120–3.
- [27] Arroyo A, Garcia P, Perez F, et al. Randomized clinical trial comparing suture and mesh repair of umbilical hernia in adults. *Br J Surg* 2001;88(10):1321–3.
- [28] Wright BE, Beckerman J, Cohen M, et al. Is laparoscopic umbilical hernia repair with mesh a reasonable alternative to conventional repair? *Am J Surg* 2002;184(6):505–8.
- [29] Berman EF. Epigastric hernia: an improved method of repair. *Am J Surg* 1945;68:84.

- [30] Lichtenstein IL. Herniorraphy: a personal experience with 6321 cases. *Am J Surg* 1987; 153:553.
- [31] Stuart AE. Taking the tension out of hernia repair [editorial]. *Lancet* 1994;343:748.
- [32] Brancato G, Privitera A, Donati M, et al. Tension-free prosthetic repair in the surgical treatment of epigastric hernia. *Ann Ital Chir* 2002;73(3):299–302.